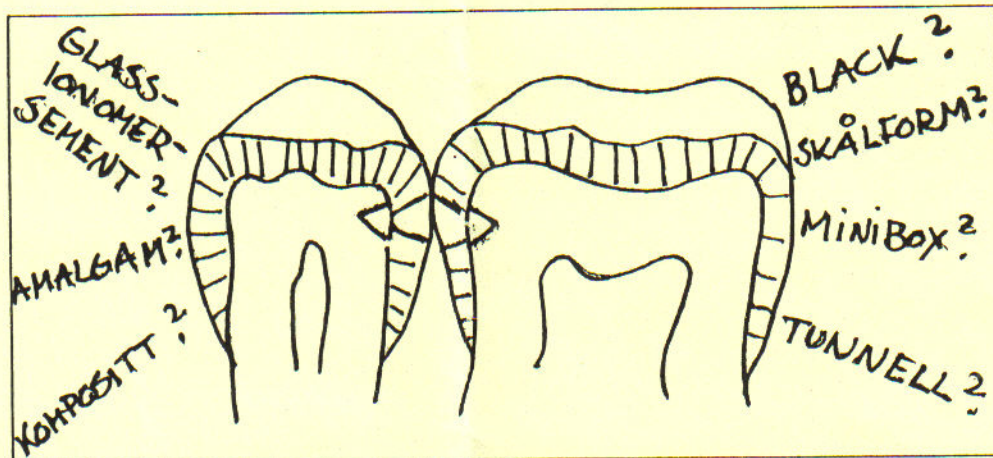




Invitasjon til vårmøte

Sted: 3 M's lokaler, Hvamveien 6, 2013 Skjetten
Tidspunkt: Onsdag 29.april kl 18.30



Fyllingsmaterialer:

- Hva velger vi ?
- Hva gjør vi ?
- Hva svarer vi ?

Asbjørn Jokstad, er invitert til å belyse dette temaet.

Vi ønsker en diskusjon på bakgrunn av brevet fra Helsedirektoratet av 6.2.1992. Det er en fordel om alle medlemmene setter seg inn i brevets innhold.

En representant fra 3M snakker om avtrykksmaterialer.

Unitrade vil vise en liten dentalutstilling.

Det blir enkel bevertning.

Påmelding til Anne S. Krogenæs, tlf.kontor 02-807941 eller skriftlig til Anne S. Krogenæs, Skøyen Terr. 4, 0276 OSLO, innen fredag 24.april.

Med hilsen OTL-styret.

Amalgam	(+)		+		+
Glassionomer	-		-		-
Komposit	-		-		+
Gull	+		+		+
Indirekte					
Komposit	-		?		-
Gull	++		+		+
Porselen	(+)	?		(+)	

Kliniske studier av ulike alternative materialer publisert siden 1990

Glassionomer

Knibbs P.J, Plant C.G. An evaluation of a rapid setting glass ionomer cement used by general dental practitioners to restore deciduous teeth. *J Oral Rehabil* 1990;17(1):1-8.

Forsten L, Karjalainen S. Glass ionomers in proximal cavities of primary molars. *Scand J Dent Res* 1990;98(1):70-73.

Smith A.J, Chimimba P.D, Kalf-Scholte S, Bouma J. Clinical pilot study on new dental filling materials and preparation procedures in developing countries. *Community Dent Oral Epidemiol* 1990;18:309-312.

Hickel R, Voss A. A comparison of glass cermet cement and amalgam restorations in primary molars. *ASCD J Dent Child* 1990;57(3):184-188.

Welbury R.R, et al . A clinical trial of the glass-ionomer cement-composite resin "Sandwich" technique in class II cavities in permanent molar and molar teeth. *Quintessence Int* 1990;21(6):507-512.

Croll T.P, Phillips R.W. Six years' experience with glass-ionomer-silver cermet cement. *Quintessence Int* 1991;22(10):783-793.

McLean J.W. The clinical use of glass-ionomer cements - future and current developments. *Clin Mater* 1991; 7:283-288.

Matis B.A, et al . How finishing affects glass ionomers. Results of a five-year evaluation. *J Am Dent Assoc* 1991;122(8): 43-49.

Verdonschot E.H, Oortwijn J.C, Roeters F.J. Aesthetic properties of three Type II glass polyalkenoate (ionomer cements). *J Dent* 1991;19: 357-361.

Swedberg Y, Malmqvist J. Glasjonomer allt vanligare i mjölkttandsbettet. *Tandläkartidningen* 1992;84(1): 11-14.

2b "Sandwich"

Grogono A.L, McInnes P.M, Zinck J.H, Weinberg R. Posterior composite and glass/ionomer composite laminate restorations: 2 year clinical results. *Am J Dent* 1990; 3(4): 147-152.

Knibbs P.J. The clinical performance of a glass polyalkenoate (glass ionomer) cement used in a 'sandwich' technique with a composite resin to restore class 2 cavities. *Br Dent J* 1992; 172: 103-107.

2c. Posteriore kompositter

Stangel I, Barolet R.Y. Clinical evaluation of two posterior composite resins: two-year results. *J Oral Rehabil* 1990;17: 257-268.

Gängler P, Hoyer I, Krehan F, Niemella S, Weinert W. Biological testing and clinical trial of a visible light-curing composite resin restorative material. *Quintessence Int* 1990;21(10): 833-842.

Ferrari M, Mason P.N, Bertelli E. A new dentinal bonding agent and microfilled resin system: a 2-year clinical report. *Quintessence Int* 1990;21(11): 875-881.

Lundin S., Andersson B, Koch G, Rasmusson C.G. Class II composite resin restorations: A three year clinical study of six posterior composites. *Swed Dent J* 1990;14(3): 105-114.

Cunningham J, Mair L.H, Foster M.A, Ireland R.S. Clinical evaluation of three posterior composite and two amalgam restorative materials: 3-year results. *Br Dent J* 1990;169: 319-323.

Schneider P.E. Seitenzahn-restauration mit composite- 4jährige erfahrungen aus der praxis. *Phillip Journal* 1990; 7(6): 264-273.

Krejci I, Krejci D, Lutz F. P-30: In-vivo-untersuchung eines seitenzahnkomposits während 2,5 jahren. Dtsch Zahnärztl Z 1990;45(12): 773-778.

Dietschi D, Holz J. A clinical trial of four light-curing posterior composite resins:two-year report. Quintessence Int 1990;21(12): 965-976.

Komatsu M, Wakui A, Obara M, Kubota M, Okuda R. Two-year clinical observation of light-cured composite resin restorations placed with a dentinal bonding agent. Quintessence Int 1990;21(12):1001-1006.

Fuks A.B, Chosack A, Eidelman E. A two-year evaluation of in vivo and in vitro class 2 composites. Oper Dent 1990;15(6): 219-223.

Heinz B. Seitenzahnrestaurationen mit komposit. ZWR 1990;99: 779-83

Normann R.D, Wright J.S, Rydberg R.J, Felkner L.L. A 5-year study comparing a posterior composite resin and an amalgam. J Prosthet Dent 1990;64(5): 523-529.

Wilson N.H, Wilson M.A, Wastell D.G, Smith G.A. Performance of Occlusin in butt-joint and bevel-edged preparations: Five year results. Dent Mater 1991; 7: 92-98.

Wilson N.H, Normann R.D. Five-year findings of a multiclinical trial for a posterior composite. J Dent 1991;19(3): 153-159.

Barnes D.M, Blank L.W, Thompson V.P, Holston A.M, Gingell J.C. A 5- and 8-year clinical evaluation of a posterior composite resin. Quintessence Int 1991;22(2): 143-151.

Dietschi D, Holz J. Klinische untersuchung von vier lichthärtenden kompositmaterialien für den seitenzahnbereich - ergebnisse nach zwei jahren (I). Quintessenz 1991;42(5): 743-752.

Stein M, Ritter G, Bienengrber V, Beetke E. Das lichthärtende komposit CuRAY-FIL eine klinische und tierexperimentelle studie. Dtsch Zahn-Mund Kieferheilkd 1991;79(3): 211-218.

Wilder A.D, Bayne S.C, May K.N, Leinfelder K.F, Taylor D.F. Five-year clinical study of UV-polymerized posterior composites. J Dent 1991;19: 214-220.

Barr-Agholme M, Odén A, Dahllöf G, Moder T. A two-year clinical study of light-cured composite and amalgam restorations in primary molars. Dent Mater 1991; 7:230-233.

Städtler P. Klinische Qualität von Luxafill- applikationen nach 1/2, 1 und 2 jahren. Z Stomatol 1991; 88(5): 269-272.

Tyas M.J, Wassenaar P. Clinical evaluation of four composite resins in posterior teeth. five-year results. Aust Dent J 1991; 36(5): 369-373.

2d. Indirekte fyllinger

Hannig M, Albers H.K. Kompositinlays aus SR-Isosit im klinischen kurzzeittest. Dtsch Zahnärztl Z 1990;45(4): 236-239.

Bessing C, Molin M. An in vivo study of glass ceramic (Dicor) inlays. Acta Odontol Scand 1990;48: 351-357.

Bessing C, Lundqvist P. A 1-year clinical examination of indirect composite resin inlays: a preliminary report. Quintessence Int 1991;22(2): 153-157.

Hannig M. Klinische erfahrungen bei der füllungstherapie mit kompositinlays. Zahnärztl Prax 1991;42(5): 162-164.

Mörmann W, Krejci I. Computer-designed inlays after 5 years in situ: clinical performance and scanning electron microscopic evaluation. Quintessence Int 1992;23(2): 109-115.

Haas M, et al . Klinische und werkstoffkundliche Erfahrungen mit Komposit- Keramik- und Goldinlays. Dtsch Zahnärztl Z 1992;47(1): 18-22.

Krejci I, Krejci D, Lutz F. Clinical evaluation of a new pressed glass ceramic inlay material over 1.5 years. Quintessence int 1992;23(3): 181-186.

Füllemann J, Krejci I, Lutz F. Kompositinlays: klinischeund rasterelektronenmikroskopische untersuchung nach einjähriger funktionszeit. Schweiz Monatsschr Zahnmed 1992;102(3): 292-298.

Ekstra tid nødvendig ved bruk av alternative materialer

Hendriks F.H, Letzel H, Vrijhoef M.M. Cost benefit analysis of direct posterior restorations. Commun Dent Oral Epidemiol 1985*13: 256-259.

Dilley D.C, Vann Jr W.F, Oldenburg T.R, Crisp R.M. Time required for placement of composite versus amalgam restorations. ASDC J Dent Child 1990;57(3): 177-183.

Kreulen C.M, et al . Evaluation of treatment times for class II composite resin restorations. ASDC J Dent Child 1991;58(4):372-377.

Bivirkningsfrekvens

" Bivirkningsfrekvensen fra dentale materialer er ikke stor, men allikevel noe vi må regne med. Dette er noe tannlegene skal være oppmerksomme på og som pasientene er nødt til å akseptere. Bivirkningsfrekvensen blir sikkert ikke mindre om vi bytter ut amalgam med andre materialer. Det treffer bare andre mennesker, på en annen måte. "

Professor Gudbrand Øilo, Vestlandsmøtet 1984.